EVALUATION OF THE EFFECT OF MONOCROTOPHOS ON FRESHWATER TELEOST, LABEO ROHITA USING HISTOLOGICAL TECHNIQUES

Project Report

MRP(S)- 1143/11-12/KLCA 021/UGC-SWRO

Principal Investigator :

Dr.R.Girija, Assistant Professor
Department of Zoology
Mercy College, Palakkad, Kerala
(Re-accredited with A grade by NAAC)

www.mercycollegepalakkad.com
email: zoology@mercycollegepalakkad.com

EVALUATION OF THE EFFECT OF MONOCROTOPHOS ON FRESHWATER TELEOST, *LABEO ROHITA* USING HISTOLOGICAL TECHNIQUES

Project Report

MRP(S)- 1143/11-12/KLCA 021/UGC-SWRO

Principal Investigator

Dr.R.Girija
Assistant Professor
Department of Zoology
Mercy College, Palakkad-678 006.

DECLARATION

I , Dr.Girija, Assistant Professor, Department of Zoology, Mercy College, Palakkad hereby declare that, the project report entitled, "Evaluation of the effect of monocrotophos on freshwater teleost, *Labeo rohita* using histological techniques" is a bonafide work done by me.

Place:

Date:

Dr.R.Girija

CERTIFICATE

It is certified that, the project report entitled, "**Evaluation of the effect of monocrotophos on freshwater teleost, *Labeo rohita* using histological techniques**" submitted to the University Grants Commission is a record of original project work carried out by **Dr.Girija, Assistant Professor, Department of Zoology, Mercy College, Palakkad** under the UGC Minor Project Scheme. This has not been previously submitted for the award of any degree, diploma or other similar title of this or any other University.

MERCY COLLEGE
Date.....

Sr. Alice Thomas

Principal
Mercy College, Palakkad

PRINCIPAL
MERCY COLLEGE
Palakkad - 678 006

ACKNOWLEDGEMENTS

I record our sincere thanks to
Dr. Sr. Alice Thomas., Principal, Mercy College, Palakkad, for the facilities kindly provided to me all through the work.

I am indebted to
Dr. M. A. Akbarsha, my research supervisor & **Dr.B.Kadalmani**, Bharathidasan University , Tiruchirappalli for permitting me to use their histology lab facilities

I owe my gratitude to
Smt. Gracy A.T., Head of the Department, Department of Zoology for the constant support and guidance provided throughout our project period.

I accord our gratitude also to
Department of Fisheries, Malampuzha from where I collected fingerlings of *Labeo rohita*

I express my profound sense of gratitude to
Dr. S. Jayasree, Associate professor and **Dr. Biji, C.P.,** Assistant Professor, Dept. of Zoology for their support during the course of work. I am indebted to Biji for permitting me to use the research microscope for capture of images.

I gratefully value the assistance of all **the lab members** at the Department for their helping hands always.

A special word of gratitude is also expressed to **the students who assisted** me in the conduct of the project for their help and assistance.

I acknowledge the benevolence of **Lord Almighty** for blessing me with good family and friends and for being with me at every step of the proceedings in our life.

The financial assistance provided by **UGC, New Delhi via the minor project** is gratefully acknowledged.

Dr.R.Girija

CONTENTS

ABSTRACT…….....……..1

1. INTRODUCTION 2
2. MATERIALS AND METHODS 13
3. RESULT 18
4. DISCUSSION 30
5. CONCLUSION .....……..34
6. REFERENCES .....……..35

ABSTRACT

The assessment of the ecotoxicological risks caused by pesticides to ecosystems is based on toxicity data and their effects on non-target organisms. Fishes are one among the groups of non-target aquatic organisms. Histological changes provide a rapid method to detect effects of pesticides, especially chronic ones, in various tissues and organs. Gills perform many important functions in the fish, such as respiration, osmoregulation and excretion. They remain in close contact with the water, considered as the primary target of the contaminants as they are sensitive to changes in the quality of the water. The present study was undertaken to determine the histopathological alterations in the gill tissues in *Labeo rohita* chronically exposed to monocrotophos. The fingerlings of freshwater fish, *L. rohita* were exposed to sub-lethal concentrations [10 – 40 mg/l] of monocrotophos in water in a static bioassay. Fishes were sacrificed after a period of 30 days the light microscopic changes associated with toxicity was studied. Organ tissue namely gills were dissected out, processesed for paraffin embedding and sections were stained in haematoxylin and eosin. Histopathological changes observed in the gill architecture included necrosis of primary and secondary epithelial cells, fusion of secondary gill lamellae as well as swelling of the primary and secondary gill lamellae, clubbing of at the tip of secondary gill lamellae etc., The histopathological alterations in the liver included karyopyknosis, karyohexis, cirrhosis, degeneration of hepatocytes and blood congestion. The intestinal histoarchetecture exhibited flattening and fusion of villi and cracked clay appearance. The study establishes the fact that histological changes in tissues could be related to environmental conditions and alterations may serve as a sensitive biomarker for pollutants existence in ecosystems

INTRODUCTION

General Introduction

Pesticide Toxicity

The Green Revolution of 1960`s has given reasonable hope for the India, being not only self sufficient in the production of adequate food and fodder for feeding its teeming human and animal population but also becoming the largest producer of some important commodities. The role played by pesticides are quite significant but have given rise to serious other health problems (Gupta, 1989). Most of the chlorinated non-degradable pesticides leave residues in various living systems for prolonged periods of their life span and are presumably responsible for a variety of known and unknown toxic symptoms (Gupta, 1985).

Pesticides have been in use for over thousands of years. Some of the early demonstrations include burning of sulphur to control insects by Romans and the use of arsenic and pyrethrum by the Chinese. By the early 20'''century, two classes of pesticides were primarily used, *viz.,* botanicals, natural chemicals derived from plant material, and preparation of inorganic salts, which were widely used as fungicides, herbicides and insecticides. The era of synthetic pesticides started with the discovery of DDT (Dichloro diphenyl trichloro ethane) in 1934, which possessed insecticidal properties. Since then, innumerable preparations have been in use in the name of insecticides, fungicides, herbicides, *etc*. Globally, about 2.5 million tons of pesticides are targeted on agricultural crops. Even though, the use of pesticides had a very positive impact in the overall increase in food production, the risks associated with this include deterioration of human health, water contamination, livestock animal poisoning and death of beneficial insects, wildlife endangerment and pesticide tolerance(Gupta,2004).

The use of pesticides in India began in 1948 when DDT was imported for malaria control and BHC for locust control. India started pesticide production with manufacturing plant for DDT and benzene hexachloride (BHC) in 1952. Despite the fact that the consumption of pesticides in India is still very low, there has been a widespread contamination of food commodities with pesticide residues, basically due to non-judicious usage. In India, 51% of food commodities are contaminated with pesticide residues (Gupta, 2004). The three commonly used pesticides, BHC (only

gamma-BHC is allowed), DDT and malathion account for 70% of the total pesticide consumption (Gupta, 2004). These pesticides are still preferred by the small farmers because they are cost effective, easily available and display a wide spectrum of bioactivity. Out of the total consumption of pesticides in India , 80% are in the form of insecticides, 15% are herbicides, 1.46% is fungicide and less than 3% are others.

It has been observed that their long-term, low-dose exposure are increasingly linked to human health effects such as immune-suppression, hormone disruption, diminished intelligence, reproductive abnormalities, and cancer. In this light, problems of pesticide safety, regulation of pesticide use, use of biotechnology, and bio pesticides are some of the possible future strategies for minimizing human exposure to pesticides. The worldwide consumption of pesticides is about two million tones per year, of which 24% is consumed in the USA alone, 45% in Europe and 25% in the rest of the world (Gupta, 2004).

There are many cases of poisoning from pesticides all over the world. In India, the first report of poisoning due to pesticides was from Kerala in 1958, where over 100 people died after consuming wheat flour contaminated with parathion Folidol E 605 (Karunakaran, 1958). Subsequently, several cases of human and animal poisonings, besides deaths of birds and fishes, have been reported (Banerjee, 1979). In Indore, out of the 35 cases of malathion (diazole) poisoning reported during 1967-1968. In another report from Madhya Pradesh, 12 humans who consumed wheat for 6-12 months contaminated with aldrin dust and BHC developed symptoms of poisoning which consisted of myoclonic jerks, generalized clonic convulsions, and weakness in the extremities (Gupta,1975). The Bhopal gas tragedy is a catastrophe that has no parallel in industry history. In the early morning of 3 December, 1984 a rolling wind carried a poisonous gray cloud past the wall of the Union Carbide plant in Bhopal, Madhya Pradesh, India. An estimated 8000 or more people died. More than 4000 animals died within minutes of exposure to the gas and almost 15,000animals suffered the toxic gas effect while surviving (over three times the officially announced total. Adverse effects included pulmonary edema which was the cause of death in most cases, with many deaths resulting from secondary respiratory infections such as bronchitis and bronchial pneumonia (Pandey, 1986; Jain and Dave, 1986).In India, such suicide poisoning may even go up to 70% because such compounds are easily available in many households. In addition to intentional exposure (suicides and homicides), workers are exposed to occupational hazards in industrial settings and operational hazards during distribution and use in the field. In developing countries

where users are often illiterate, ill-trained, and lacking appropriate protective devices, the risks are magnified. The Poison Information Centre in National Institute of Occupational Health in Ahmedabad reported that organophosphorus pesticides were responsible for the maximum number of poisonings (73%) among all agricultural chemicals (Dewan and Sayed, 1998). Studies on 356 workers in four units manufacturing HCH revealed neurological symptoms (21%) with significant increase in liver related enzymes which were related to the intensity of exposure (Nigam *et al.,* 1993). Observations confined to health surveillance in male formulators engaged in production of dust and liquid formulations of various pesticides (malathion, methyl parathion, DDT, and lindane) revealed several types of adverse effects and reproductive problems (Gupta, 2004). A cytogenic study revealed a significant increase in chromatid breaks and gaps in chromosomes in the peripheral blood in grape garden workers exposed to pesticides (Rita et al., 1987). Separate studies conducted in malaria spray men spraying HCH, DDT, malathion, and cyfluthrin, showed increased levels of serum IgG (malathion exposure) and serum IgA (cyfluthrinexposure) (Karnik et al., 1993).

Pesticides have been primarily criticized for the presence of their residues in various samples of human blood, human fat, human milk, and fat samples and food commodities. This could either be due to direct exposure or indirectly through the food chain. In India, National Occupational Health Centre (NIOH) and Indian Council of Agricultural Research Institute (ICAR) are carrying out monitoring of health status and pesticide-residues in various samples. Analysis of samples of human blood, human fat, human milk, and fat samples was carried out by the National Institute of Occupational Health, Ahmedabad. Residues of organochlorine insecticides, especially DDT and HCH have been detected in man and his environment the world over. However, by comparison very high levels of these have been reported in human blood, fat, and milk samples in India (Bhatnagar, 2001). Higher level of these chemicals in human samples and in mother's milk is a reflection of their increased burden and their translactation passage. Residues of pesticides from food commodities were monitored by All India Co-coordinated Research Project on Pesticide Residues under the Indian Council of Agricultural Research, New Delhi, through their centers located in different parts of the country. Recently, analysis of bottled water, colas and other soft drinks carried out by the Centre for Science and Environment, New Delhi revealed very high content of pesticide residues (Anonymous, 2003a, b, c).

Aquatic toxicity of pesticides

In recent years serious efforts are being made to increase crop production through intensive agricultural practices. This has resulted in a large scale use of pesticides which is on the increase daily**.** Pesticides have brought tremendous benefits to mankind by increasing food production and controlling the vectors of man and animal diseases, hence, they play a prominent role in promoting our health and economy (Malla *et al*., 2009). Pesticides are one of the most potentially harmful chemicals introduced into the environment (Rathod & Kshirsagar, 2010). Its contamination in aquatic system, has been because of its over use in agricultural fields and entry of the pesticides into the water bodies which is a great threatening problem all over the world (Bouregeois *et al*., 1993; Nayak *et al*., 1995; Kalavathy *et al*.,2001). Although, it has great advantage in the field of crop production, the extensive use of pesticides resulted in a large reduction of fish production in the field of aquaculture. In our country the usage of various pesticides causes dreadful impacts on other living freshwater organisms particularly, to sensitive animals as fishes and prawns (Selvarani & Rajamanickam, 2003; Park *et al*., 2004). Several of banned pesticides are still used on a large scale in developing countries and continue to pose dreadful environmental problems as well as health hazards (WHO, 1989). Although, pesticides have contributed considerably to the welfare of the human being, yet they destroy target as well as non target organisms in a field. The extensive use of pesticides has resulted in large reduction in fish production, not only in capture fisheries sector but also in aquaculture. The indiscriminate use of pesticides has been identified as a cause for many previously unexplained fish kills in fish farms in other parts of the world. Pesticides usually get into the aquatic environment through accidents or through run off from surroundings farmlands. This later results in fish mortality and morbidity (Oloruntuyi *et al*.,2000)

Pesticides have an innate capacity to cause damage to biological system. Its toxicity range is large in aquatic organisms and its variation depends on the age, sex, size, and physiological, biological as well as environmental factors. Poisoning effect in fishes is mainly due to the poisoning metabolism. Biochemical values indicate the intensity of toxic action of the pesticides. The cumulative toxicological impact of pesticides mixture causes toxic impairment in the metabolic, physiological and histological analysis in vital tissues (Stegemen *et al*., 1992; Simon *et al*., 1983). Pollutants also may cause additive harmful effects on the fish.

Pesticide usage leads to a great decrease in protein synthesis and cellular

degradation. It also causes nucleic acid depletion in freshwater fishes (Rathod & Kshirsagar, 2010). Pesticide usage causes significant changes in haematological parameters like erythrocyte sedimentation rate [ESR] that makes the fishes lethargic and reduces its feed intake as well as impairs its equilibrium (Malla *et al*., 2009). Its effects on fishes create a dark colouration on its body before its death. It`s uses also effects a critical damage to the gills and gill arches, kidneys, liver, heart, degrees of degenerative and necrotic changes in tubular epithelium of fishes (Rao *et al*.,2005).

Monocrotophos

Monocrotophos is an organophosphate insecticide, which is acutely toxic to birds and humans. The IUPAC name of Monocrotophos is Dimethyl (E)-1-Methyl-2-(methyl-carbomyl) vinyl phosphate. It`s molecular formula is $C_7H_{14}NO_5P$ with a molecular mass 223.2g/mol and density of 1.33g/cm3. It's melting and boiling point is 55 degree Celsius and 120 degree Celsius at 0.0005 mmHg.

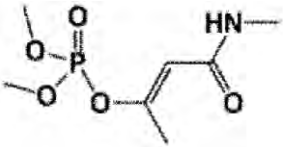

The structure of Monocrotophos is-

Dimethyl *(E)*-1-methyl-2-(methylcarbamoyl) vinyl phosphate

This pesticide is now out of patent and is produced by at least 15 manufacturers.40% total annual production of this pesticide has been produced by NOVARTIS and it has been also manufactured and exported by companies in India, China, Brazil and Argentina. Among all insecticide products, the total scale of monocrotophos in 3% has been registered in approximately 60 countries. These insecticides are used in various countries on its performance, safety, chemistry, and environmental aspects. In the European countries, it has been registered in Austria, France, Spain, Italy and Greece. It has been mainly applied against cotton pests. It is also used on citrus, olives, rice, maize, sorghum, sugar cane, sugar beet, peanut, potatoes, soyabean, vegetables, ornaments and tobacco.

The usage of this insecticide resulted in the total destruction or extinction of bird species mainly swainson's hawks. It has been banned in US and many other countries due to its toxicity. The use of Monocrotophos is forbidden on crops grown in United States but the crops that have been cultivated using this insecticide are still directly imported to US for consumption. Its impacts will always be most profound on the regions and inhabitants of the region in which it is used; hence, awareness has been given to the people about this highly toxic compound and its impact on the

environment and health. It has been highly hazardous which is highly responsible for death resulting from accidental or intentional exposure *(www.wikipedia.org)*.

Monocrotophos is more dangerous to the environment, and has a half life of 14-21 days at pH 9 and 25 degree Celsius. Its rate is directly proportional to the temperature and pH. Its degradation occurs rapidly on exposure to sunlight while it slowly degrades on darker condition. Monocrotophos has high mobility in soil and it possesses potential for ground water contamination. It also causes high toxic effects on birds, wild life and in bees as well as to shrimps and crabs, moderately toxic for fishes and non-toxic for microorganisms. The most recent avian mortality attributed to monocrotophos has been reported in Argentina were 20,000 hawks died over an area of approximately 200- 250 km in 1996. The major manufacturer Novartis joined meetings to prevent or ban the usage of monocrotophos all over the world and also has conducted a campaign to inform farmers about its toxicity.

It has been found in low levels in food products or residues such as dried currant, dwarf beans and also in other products. Its maximum residue limit ranges from 0.02-1mg/kg and the acceptable daily intake is 0.0006mg/kg body weight. Its metabolites have been identified in the milk, muscle and liver of cows and in the milk of goats due to the ingestion of the chemical. Its exposure can be avoided by the use of flaggers, wearing of full protective clothing along with a respirator, when it is mixed and sprayed on tall crops. All equipments, protective clothing should be thoroughly washed off after use and clothing should be laundered separately from family clothing. Unprotected workers should be kept out of the treated areas for 48 hours. Manufacture, formulation, agricultural use and disposal of monocrotophos should be carefully managed to minimize contamination of the environment.

- There are several control actions were taken against Monocrotophos in various countries are:-
    - In Germany-it is not handled by adolescents, pregnant and nursing women.
    - In Indonesia-it has been banned for use in rice in 1986 because of insect resistance and certain formulation phased out in 1994.
    - In Kuwait-its use has been severely restricted on plants up to flowering stage
    - In Malaysia- registration for use only in coconut and oil palm by trunk injection.
    - In Philippines- in 1990, the fertilizer and pesticide authority issued

circular no.01, which included a severe restriction on monocrotophos to use only in bean fly control. A six month phase out period took effect from 29 Sep 1993.

- In Srilanka- its use is severely restricted and its import is prohibited since July 1995.
- In USA-voluntarily withdrawn by the registrant in 1989.before withdrawal it could be used only by certified applicators. No remaining uses are allowed. Main concern in toxicity to non-target species especially birds.

Monocrotophos Toxicity

Monocrotophos is commonly known as azordin, which is a systematic organophosphate insecticide used in controlling a variety of insect pests. This has been generally applied in aerial spraying so that it becomes easier for this pesticide to contaminate nearby areas by drifting. It is considered to be less lethal to fish than various other insecticides (Thomas and Murthy, 1976). They do not undergo rapid degradation and get accumulated in freshwater bodies in harmful concentration (Eichelberger and Lichtenberg, 1971). It is extensively used in agricultural practices throughout the world. An experiment done by Agrahari *et al*., 2006 using biomarkers of Monocrotophos in freshwater fishes showed variation in total protein, lipid peroxidation and acetylcholinestrase in different tissues such as gills, liver, brain and muscles. Its protein level were found to be depleted in all tissues on exposure to lethal and sub lethal concentration while its lipid level increased due to the inhibition of lipase activity and other biomarkers of lipid metabolism. It also causes a significant inhibition of brain acetylcholinestrase indicating its effects on nervous system.

It is highly toxic orally, by inhalation and absorption through the skin. Its poisoning symptoms include excessive sweating, headache, weakness, giddiness, nausea, vomiting, hyper salivation, abdominal cramps, diarrhea, blurred vision and slurred speech. Inhalation or skin contact may increase the susceptibility to the pesticide without showing immediate symptoms. The acute oral toxicity in male and female rats is 23mg/kg and 18mg/kg respectively and its acute dermal toxicity in rats is 354 mg/kg. The effect of Monocrotophos in rabbits noted that it irritates the eyes and causes reversal of corneal capacity while on human health it has been reported to result in pain, bleeding, tears, pupil constriction and blurred vision on direct contact with eyes.

Its high toxicity may cause various health hazards such as it affects the central

nervous system, producing inco-ordination, slurred speech, loss of reflexes , weakness, fatigue, involuntary muscle contraction, twitching ,tremors of the tongue or eyelids eventually paralysis of the body extremities and the respiratory muscles. In severe cases there may also be involuntary defecation or urination, psychosis, irregular heartbeat, unconsciousness, convulsions of cornea. Ingestion of 120mg monocrotophos can be fatal. It is a potent cholinesterase inhibitor. The no observed effect level (NOEL) in rats is 0.03 mg/kg. It is slightly irritating to the skin and mildly irritating to the eyes. It also causes delayed neuropathy. A study on the Egyptian farmers shows that 50% of them has been affected by neurological defects such as superficial or deep sensory loss and decrease or lost reflexes in their ankle and knee. Monocrotophos does not have any carcinogenic effects even at high doses. This has been proved by an experiment on rat at a high dose of about 0.45mg/kg/day. Rats when exposed to monocrotophos at a concentration of about 97-308 mg/m^3 for one hour where its result did not show any significant carcinogenic lesions but resulted in decreased fertility, pup viability, weight and also partly attributed to depressed maternal lactation on reproductive organs. The teratogenic defects were not yet reported even at the usage of high monocrotophos amount.

Ali and Kumar, 2008 conducted an experiment on long-term genotoxic effect of Monocrotophos in different tissues of freshwater fish *Channa punctatus* (Bloch) using alkaline single gel electrophoresis to detect the DNA damage of different tissues using genotoxicity biomarkers. The DNA damage was measured in the gills, kidney and lymphocyte in fishes exposed to different sub lethal and non-lethal concentration of Monocrotophos. The highest DNA damage was found in gill cells, which was more sensitive than the kidney cells and lymphocytes. In an experiment conducted by Andre Luis da Cruz ……..to study the effect of sublethal concentrations of Monocrotophos on the aggressive behavior of fishes *Astyanax altiparanae* Garutti and Britski (lambari) and *Oreochromis niloticus* (Nile tilapia). This resulted in the decreased aggressiveness in lambari but in tilapia an opposite effect was detected which shows a species specific effect of the monocrotophos on aggression.

In mosquito fish, *Gambusia affinis* the effect of monocrotophos on locomotor behavior and gill architecture was studied by Rao *et al*., 2005 They reported that under stress , they altered their locomotor behavior such as distance travelled per unit time and swimming speed with respect to the length of the exposure. Inhibition in the activity of brain AchE and deformities in the primary and secondary lamella of gill resulted in failure of exchange of gases. The extent of damage in gill was dependent on the duration of exposure. The inhibition in brain AchE activity and structural

alteration in gill were responsible for altering the locomotor behavior of fish.

An experiment on the basis of sub- lethal effects of monocrotophos on some haematological Indices of African Catfish *Clarias gariepinus* by Yaji and Auta, 2007 showed a reduction in packed cell volume and TEC in fish exposed to various toxicant concentrations than in control groups. TLC, neutrophil and lymphocyte shows significantly higher level than in controlled group. This shows that sub-lethal concentration of Monocrotophos is harmful to *Clarias gariepinus,* therefore, its hence the usage close to water bodies for fish production is dangerous.

Labeo rohita

Labeo rohita is the binomial name of freshwater fish rohu. It is a fish of carp family Cyprinidae which has been commonly found in rivers and freshwater lakes in andaround South Asia and South East Asia(Plate.1, Fig.1a,b). It is an herbivore that has been treated with delicacy in Bangladesh and the Indian states of Assam, Orissa, West Bengal, Bihar and Uttar Pradesh. It is one of the sacred food items of Kayastha community of UP that has been eaten on all auspicious occasions. It has been known in different languages in different names such as rehu in Hindi, rui in Bengali, rou in Assamese and Syltheri and rohu in Malayalam. In Kerala it has been cultured on agricultural basis. It is a non-oily white fish that has been popular in Bangladesh, Thailand, northern India and Pakistan.

During its early stages of life cycle, it eats mainly zooplankton but in adult stage it feeds mainly on phytoplankton and submerged vegetation. It has modified, thin hair-like gill rakers, suggesting that it feeds by sieving the water. It is diurnal, solitary and reaches sexual maturity between two and five years. In nature, it spawns in the marginal areas of flooded rivers. When cultured, it does not breed in lentic environment, so induced spawning becomes necessary (*Labeo rohita (TSN) 163681).*

The rohu is deep fried and served hot as an appetizer, as part of an Oriya and Bengali meal. It is also stuffed inside pointed gourd to make potoler dolma which is considered a delicacy. Rohu is also served deep fried in mustard oil, as kalia which is rich gravy made of concoction of species and deeply browned onions and tok, where the fish is cooked in a tangy sauce made of tamarind and mustard. Rohu is also very popular in Northern India and Pakistan such as in the province of Punjab. In Lahore it is a specialty of lahori cuisine in lahori fried fish where it is prepared with batter and spices. It is also very popular food fish in Iraq.

Background and Objective of the present study

Pesticides have several ecological impacts. In tropical countries, pesticides are applied to soil and which are washed to nearby water bodies where they affect

aquatic animals. The principal pathway of pesticide impacts is that of water contaminated by pesticides runoff. All the pollutants released on land will eventually find their way to the rivers and sea as the final repository. Since estuaries are the links to the freshwater and marine systems, they contain a variety of anthropogenic chemicals referred to as xenobiotics, viz. oil derivatives, heavy metals, pesticides, fertilizers, polychlorinated biphenyls, etc. All the organic xenobiotics have the potential to affect normal physiology of aquatic animals.

Fish and aquatic animals are exposed to pesticides in three ways namely (i)direct absorption through the skin by swimming in pesticide contaminated waters, (ii) direct uptake of pesticides through the gills during respiration, and(iii) drinking of pesticides contaminated water or feeding on pesticide contaminated prey. Exposure of fish and other aquatic animals to a pesticide depends on its biological availability, bioconcentration, biomagnifications and its persistence in the environment. The organophosphorus pesticide monocrotophos 36% is extensively applied as a pesticide in agriculture, food storage shelters and pest control programs. The kinds and amounts of pesticides applied to environments are almost out of control, and about one-third of organophosphorus pesticides (OP`s) are selectively toxic to fishes (Aguiar et al., 2004).

Fishes have been widely used as models to a. evaluate the health of aquatic ecosystems and b. in toxicological pathology studies (Law, 2003). Research in fish has demonstrated that mammalian and piscine systems exhibit similar toxicological and adaptive responseswith regard to haematological parameters. This suggests that piscine models, in addition to traditional mammalian models, may be useful for further understanding the mechanisms underlying the haematological response.

Pesticides drained to the aquatic environment are primarily of agricultural origin and may also stem from effluents of manufacturing plants. The fresh water aquaculture system constitutes one third of the total fish production of India and the major carps (*Catla catla, Labeo rohita and Cirrhinius mrigala*) being the dominant species. Aquaculture areas usually get exposed to influx from surrounding water bodies particularly during rainy seasons. Therefore, the contamination likely to be present in the water bodies may affect the aquaculture produce. Most of the toxicological studies in fish are confined to the effects of pesticides on oxidative stress and haematological changes, therefore a study on the fingerlings is envisaged in this study.

Since there is great concern about toxic hazards in the aquatic ecosystem

due to pesticides, either from surface run off from paddy fields or through direct application into ponds for the control of parasites , it is necessary to study the cellular changes in fish tissues associated with this toxicity. The changes affected in fishes are more or less dose dependent.

Pesticides are the substances that cause great toxicity in different organs of living organisms. Monocrotophos is a widely used and extremely dangerous insecticide. The effects of organochlorine pesticides on fishes have been experimentally recorded by several workers (Kumar and Pant,1985; Ali and Kumar,2008). The toxicity of benzene hexachloride has been studied by Bhatia, 1971 in *Cirrhinus mrigala* and *Colisa fasciata*. Considerable interest has been shown in recent years in histopathological study while conducting sub-lethal tests in fish. Histological changes associated with pesticides in fish have been studied by many authors (Narayan and Singh, 1991; Mercy *et al*., 1996).

Indian major carp (*Labeo rohita*), being the prime cultured species in poly-culture practices in India, occupy a prominent position in the aquatic system, hence the impact of monocrotophos on the cellular level of this candidate species was chosen for the present study.

The main objective of the present study was to evaluate the toxicity of MC with special reference to

a. Determination of lethal concentration (LC_{50}) of monocrotophos in fingerlings of *L. rohita*.
b. Effect of sub-lethal concentrations of monocrotophos on

- Behavioral responses
- Histoarcheitecture of Gill, Liver & Intestine in freshwater teleost *Labeo rohita*.

The data on toxicity and effects of pesticides on non-target organisms, as fishes can help in

a. Assessment of ecotoxicological risks caused by the pesticides to ecosystem.
b. Create awareness to the people about MC and its impact on the environment and health.

MATERIALS & METHODS

Test Animal

One hundred and fifty fingerlings of *Labeo rohita* (Rohu) weighing about 5.2 ± 1.3g and having a mean body length 6.3 ± 2.5cm collected from the Department of Fisheries, Malampuzha, Palakkad, were used for the toxicity test using monocrotophos (MC) (Fig.1a,b). The fishes were brought to the laboratory and acclimatized for more than 15 days in glass troughs of 6L capacity before starting the experiment. The troughs were well aerated, and the physical and chemical parameters were kept nearly constant. During this period, and also during the experiment, the fingerlings were fed *ad libitum* with fish food obtained from the fisheries department.

Test Containers

Glass troughs of 6L capacity were used as test containers. The fishes were briefly bathed in potassium permanganate solution (5mg/l) before introducing them into the experimental areas to avoid introduction of diseases.

Test Medium

An organophosphate insecticide monocrotophos (MC) (36% SL) supplied by Sree Ramcides Chemicals Ltd., Pudukkotai, TN, India was used for the experimental study.

Experimental Design

Range Finding test

The range finding bioassay was conducted by exposure of fishes exposed to a range of sequential concentrations (1,10,100,100mg/l) of MC. Six fishes were released into glass troughs containing 6L of water and sequential concentrations of MC. Mortalities were recorded at 24, 48, 72 and 96h and dead fishes were removed immediately.

Static Bioassays

Acute Toxicity Testing - Determination of lethal concentration (LC_{50})

To determine the (LC_{50}) of MC, six fishes of approximately equal size were released into different glass troughs, containing different concentrations (10,20,40, 60,80,100, 120 mg/l) of MC. Lethal concentration (LC_{50}) was determined. Control fishes were

maintained separately and mortality was recorded at 96h. The dead fishes were removed immediately.

Chronic Toxicity Testing - Sub lethal exposures

Six concentrations (10,20,40,60 mg/l) were selected for sub lethal exposures for 30 days. One group was maintained as control in a glass trough tank containing MC free water. Fishes were fed with commercial fish feed, and the tanks were kept well aerated.

Assessment of Histopathological Parameters

At the end of exposure period, control and test fishes were sacrificed, and gill, liver and intestinal tissues were dissected out (Fig.2) and processed for histopathological analysis.

Histopathological Analysis

The histology of gills, liver and intestine was studied adopting the routine paraffin method (Humason, 1979) .

Light Microscopic studies adopting paraffin embedding

Reagents:

Physiological saline (0.9%): 0.9g of sodium chloride in 100 ml of distilled water.

10% buffered formalin: Prepared by adding 100 ml of 40% formaldehyde, 900ml of distilled water, 6.5 gms of anhydrous Na_2HPO_4 and 4 gms of $NaHPO_4.H_2O$.

Harris` hematoxylin: It was prepared by dissolving 1g of hematoxylin in 10 ml of absolute alcohol. 20g of ammonium alum, previously dissolved in 200 ml of hot water was added to the above. This solution was quickly boiled and 0.5 g of mercuric oxide was added to it upon which the solution turned to dark purple colour. It was cooled rapidly under the tap and filtered before use. 8 ml of glacial acetic acid was added after cooling to sharpen nuclear staining.

Eosin: 0.5 g of water soluble eosin (w.s) powder was dissolved in 30 ml of distilled water and made upto 100 ml with 70 ml of alcohol.

Procedure:

Gill, liver and intestine dissected out from the control and experimental fishes , were blotted free of blood and mucus, washed thoroughly in physiological saline, cut into pieces of desired size and fixed in 10% buffered formalin immediately after autopsy. Fixation was carried out at room temperature for 24 hrs, after which the tissues were transferred to 70% alcohol. Several changes of 70% alcohol were given until traces of fixative disappeared from the tissues. The tissues were then dehydrated by passing through ascending grades of alcohol, cleared in xylene, infiltrated with molten paraffin, and finally embedded in paraffin wax (58°C M.P). 3-5µm thick transverse and longitudinal sections were obtained using a rotary microtome (Leica, Germany). The sections, thus obtained, were stained in Harri`s hematoxylin and eosin, dehydrated using alcohol, cleared in xylene and mounted using DPX. The stained slides were observed in a LaboMed Olympus research microscope. Images were captured through a CCD camera in a computer and processed using Axiovision software.

Microscopy and Photomicrography

Light microscopy was conducted under Labomed Research Microscope with lens combination of 10x eye piece and 10x, 20x and 40x objectives. Images were captured by CCD camera and processed.

Statistical Analysis

Lethal concentration (LC_{50}) was calculated on the basis of plotting a graph between percentage of mortality of fishes and varying concentrations of MC. The descriptive data was given as a mean ± standard deviation (SD). The `t` test was applied to determine the level of significance.

EXPERIMENTAL DESIGN

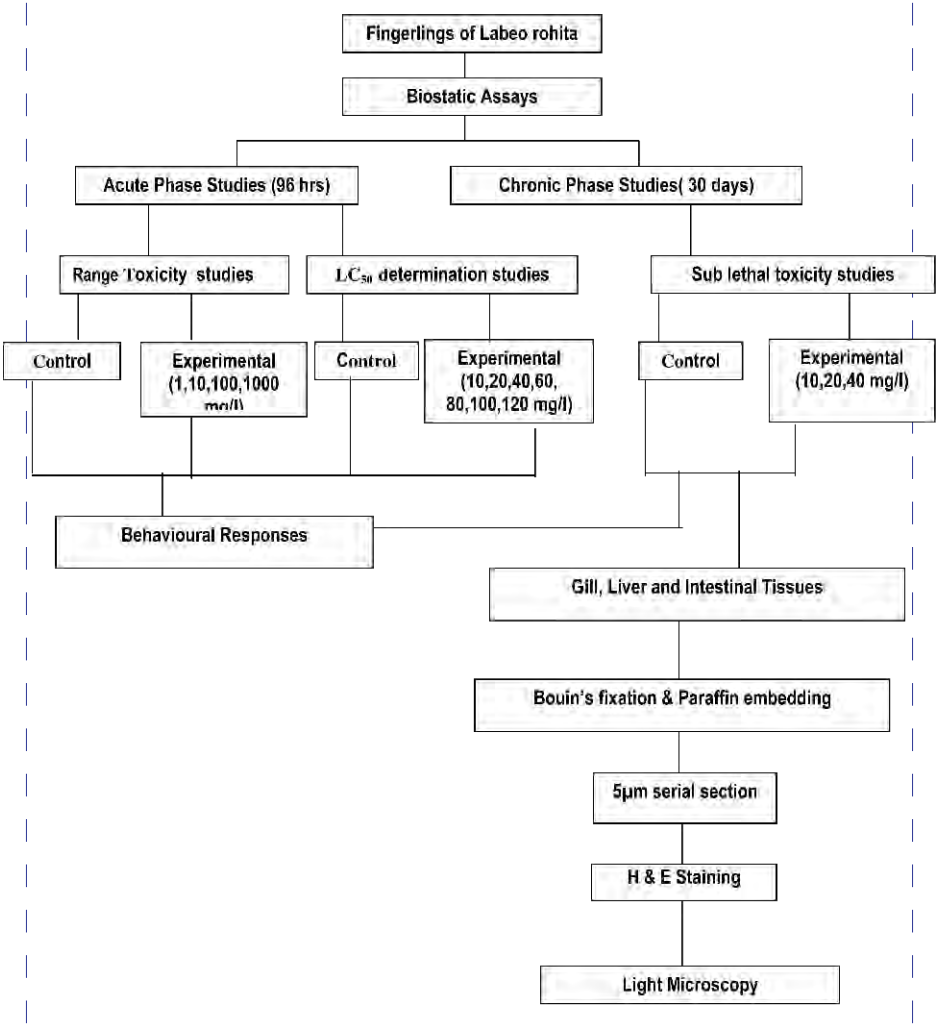

Fig.1 a. Picture of *Labeo rohita*

Kingdom: Animalia
Phylum: Chordata
Class: Actinopterygii
Order: Cypriniformes
Family: Cyprinidae
Genus: Labeo
Species: rohita

Fig.1 b.Systematic Classification of *Labeo rohita*

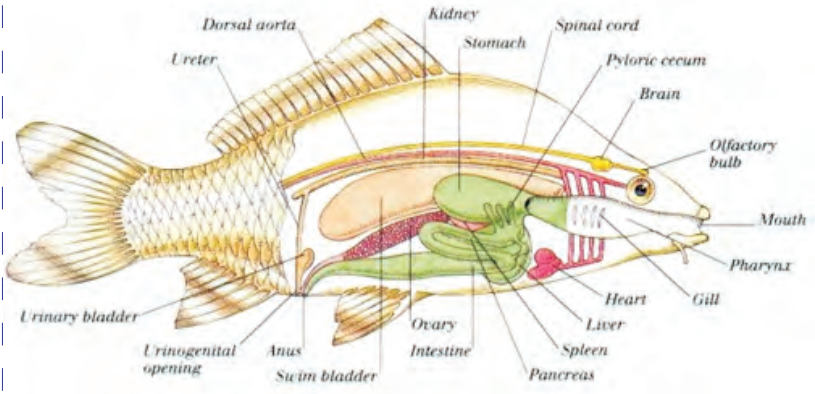

Fig.2. Dissection diagram *of Labeo rohita* showing the position of Liver, Gill and Intestine

RESULTS

Range Finding tests

The range finding test carried out for concentration of MC between 1-1000mg/l for a period of 96hr showed no mortality up to concentration of 1- 100mg/l till 56 hrs while at 1000mg/l MC concentration, 100% mortality was observed (Table. 1) within I hr of exposure, hence, the no observed effect level (NOEL) with respect to mortality was below 1000mg/l (Table.1). Therefore, it was concluded that the lethal concentration (LC_{50}) of *Labeo rohita* is between 1 and 100 mg/l of MC.

Acute Toxicity Testing –Determination of Lethal concentration (LC_{50})

The lethal toxicity study was performed for the concentration of MC ranging from 1-120mg/l. The exposure of fish to 96hr, at a concentration of 10mg/l of MC showed 16.6% mortality, while at concentration of 60mg/l about 64% mortality was noticed. The graphical analysis of percent mortality against varying concentrations of MC shows that the lethal concentration (LC_{50}) for 50% mortality of the fishes at 96hr was 48.5 mg/l for *Labeo rohita* (Fig.3).

Effect on behavioural changes

- The release of fish into water containing lethal and sub-lethal concentrations monocrotophos solution immediately resulted in
    - very fast and erratic swimming, which, however, calmed down into normal movements in all the experimental groups
    - fishes started scratching their nostrils at the bottom of the trays and frequently came at the water surface for gasping air in the experimental groups
    - repeated closing and opening of the mouth and operculum with a surfing phenomenon was also noticed.
    - After 30 minutes their movements slowed down but they continued to swim near water surface. Thereafter, fishes showed irregular erratic and some time jerky movement (imbalanced swimming) that was on increase as exposure period increased. Variations in the schooling behavior of the fishes were observed.
    - In Group treated with 10,100 mg/l, the fishes were found to show a grooming behavior (Fig.4)

- At high doses 1000mg/l , lose of body equilibrium and haemorrhage occurred which manifested itself as red colour and finally all fishes died. 100% of the fishes subjected to acute poisoning (1000mg/l) had died at the end of 1 hr after exposure (Fig.5)

Therefore, the no observed effect level (NOEL) with respect to mortality was below 1000 mg/l. Control fishes were free of such behavioural changes.

Effect on gill tissue

Under light microscopy, gill tissue of control group fish appeared to be normal made of primary lamellae arranged in double rows. Secondary lamellae arise from these filaments. Secondary lamellae are lined by squamous epithelial cells. Histologically, the gills comprise of epithelium, endothelium, pillar cells, fibrous and cartilaginous support stroma in primary lamellae and specialized cells like mucous cells, salt cells, eosinophil, granule cells and fixed macrophages (Figs.6,7). Results of the experimental groups are documented in Figs.6-15. Histopathological changes in Group 1 did not show much variation from the archeitecture of the control gill, but in Group 2, 3 and 4 alterations in histoarcheitecture was almost similar with immense variation form control gill . The distinct histopathological change noticed was significant swelling at the tips of secondary gill lamellae due to lamellar oedema (Figs.8, 9; Figs.10, 11, 13) and hypertrophy of epithelial cells. Another distinct feature was clubbing of lamellae in the secondary gill lamellae (Figs.12, 14). It is also evident from the photomicrograph that lamellar fusion has taken place due to prolonged exposure to monocrotophos (Fig.15). Complete separation of the oedematous respiratory epithelium of primary and secondary lamellae with necrosis of epithelial cells was also noticed (Figs. 11, 15).

Effect on liver tissue

In control fishes, hepatocytes were normal, polygonal in shape with a smooth surface, there was little intercellular space. The cytoplasm had particulate appearance and was marginally vacuolated. The nucleus was almost spherical, highly heterochromatic and contained prominent nucleoli (Fig.16). In liver histology of control group, the hepatocytes were normally arranged in cords of cells (Fig. 16) In the present study, the liver of *L. rohita*, treated with sub lethal concentrations of monocrotophos showed congestion of blood vessels (Fig.17,18), and nuclear vacuolization (Fig.19). The exposure of sub lethal concentrations of monocrotophos caused extensive cirrhosis

along with pyknotic nuclei (Fig.20,21,22). Karyopyknosis which is marked by irreversible condensation of chromatin, which was followed by karyorrhexis marked by fragmentation of the nucleus in necrotic cells was also observed (Fig.23). The displacing and compressing the nucleus karyorrhexis was also observed ,whereby its chromatin is distributed irregularly throughout the cytoplasm, karyopyknosis, nuclear and cytoplasmic vacuolization (Fig.24), cytoplasmic degeneration or collapse leading to increase in size i.e. ballooning degeneration (Fig.23,24), and the pyknotic nuclei released were seen pushed to the sinusoids(Fig.25,26) , in the most worse condition worn out hepatocytes along with pyknotic nucleus were seen in the sinusoids signifying complete degeneration of hepatic tissue (Fig.27).

Effect on Intestinal tissue

The fishes showed the presence of intact epithelium and villi in the sections of control intestine. In the fishes exposed to sublethal doses of MC degenerative effects were evident in the mucosal lining and villi of the intestine. The villi tend to become flattened, and there is sloughing off of the mucosal lining (Figs.28,29). Hypertrophy of epithelial cells, swelling or oedema of lamina propria (Figs.30,31,32), and fusion of villi due to excessive hypertrophies, ultimately leading to rupture of villi at tip (Figs.34,35), are also evident. Flattening of microvilli and a cracked clay appearance of the tissue are likewise apparent(Figs.29,30,33,35).

Range Toxicity Studies

Table. 1: Table showing the results of Range toxicity studies

Groups	Conc. of MC (mg/l)	Remarks
Control	---------	No death
Experimental	1	NOEL of MC; reported death only after 56 hrs. (NOEL-No observed effect level)
	10	
	100	
	1000	100% of the fishes subjected to acute poisoning died at the end of 1hr after exposure

Figure 3: Graph depicting the LC_{50} concentration (mg/l) of Monocrotophos

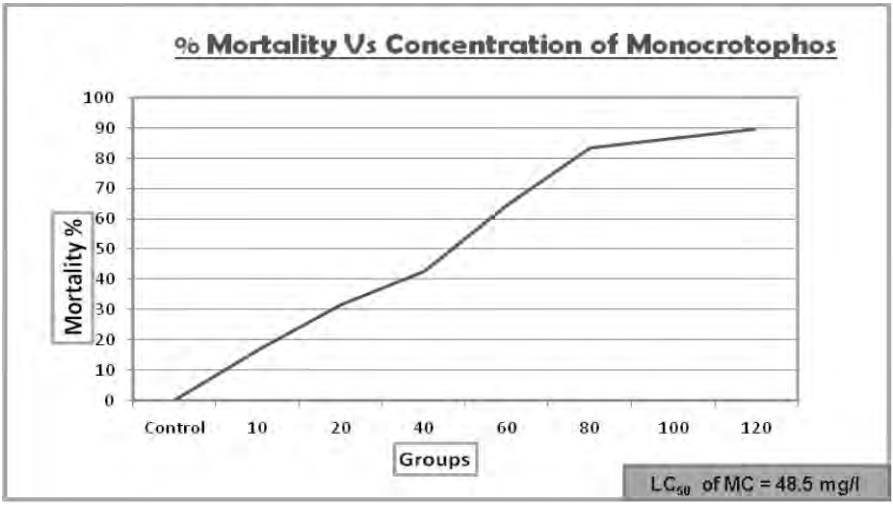

Effect on behavioural changes



Fig.4 Group treated with 10, 100 mg/l MC, fishes showing a grooming behavior

Fig.5 Group treated with 1000 mg/l MC, fishes dead at 48hrs

Effect on Gills

Histopathological changes observed in the gill architecture included

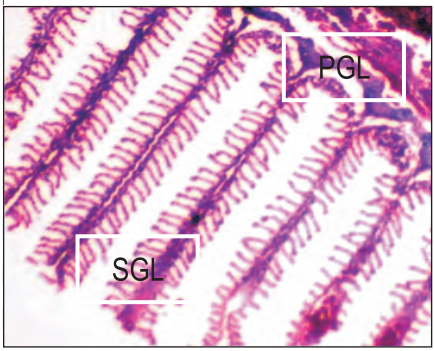

Fig. 6. H & E stained photomicrograph showing the histology of a control gill tissue of *L. rohita*. PGL-Primary Gill Lamellae; SGL-Secondary Gill Lamellae. (x100).

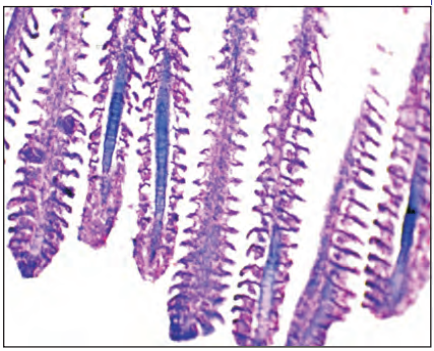

Fig. 7. H & E stained photomicrograph of monocrotophos treated gill tissue of *L. rohita* showing swelling of the gill epithelium (arrows) of Secondary Gill Lamellaeat its tip . Note the dilation of blood vessels in SGL (x100).

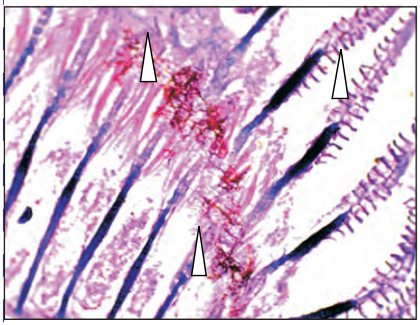

Fig. 8. H & E stained photomicrograph of monocrotophos treated gill tissue of *L. rohita* showing swelling and erosion of the gill epithelium (arrows) of Secondary Gill Lamellae and blood vessels dilated. Note the dilation of blood vessels in SGL(x100).

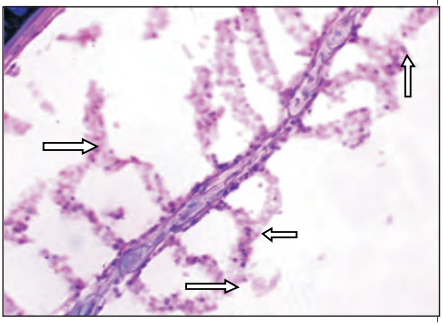

Fig. 9. H & E stained photomicrograph of monocrotophos treated gill tissue of *L. rohita* showing curling and clubbing of (arrows) Secondary Gill Lamellae. Note the dilation of blood vessels in SGL (x400).

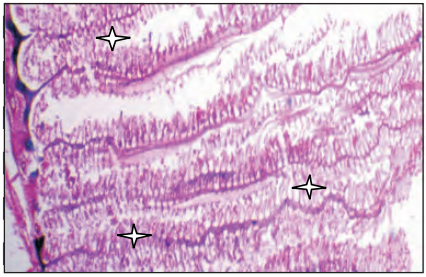

Fig.10. H & E stained photomicrograph of monocrotophos treated gill tissue of *L. rohita* showing interlamellar bridge formation or fusion (asterisks) of Secondary Gill Lamellae. (x100).

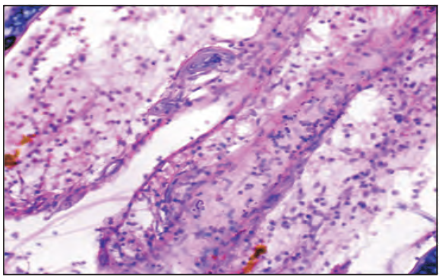

Fig. 11. H & E stained photomicrograph of monocrotophos treated gill tissue of *L. rohita* showing mucoid metaplasia (asterisks) in the Secondary Gill Lamellae. (x400).

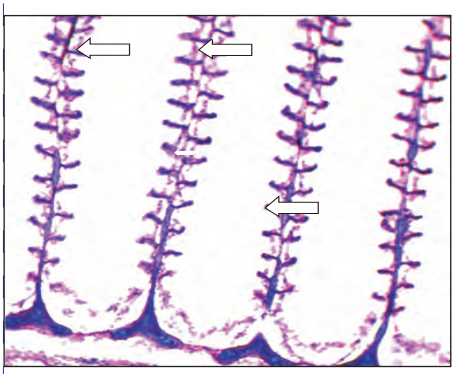

Fig.12. H & E stained photomicrograph of monocrotophos treated gill tissue of *L. rohita* showing epithelial cell degeneration (arrows) in the Secondary Gill Lamellae. (x200).

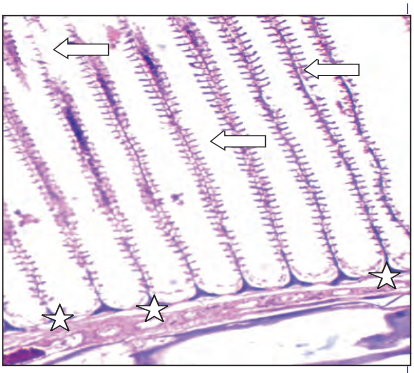

Fig. 13. H & E stained photomicrograph of monocrotophos treated gill tissue of *L. rohita* showing epithelial cell degeneration in the Secondary Gill Lamellae (arrows) and dilation of Primary Gill Lamallae (asterisks). (x100).

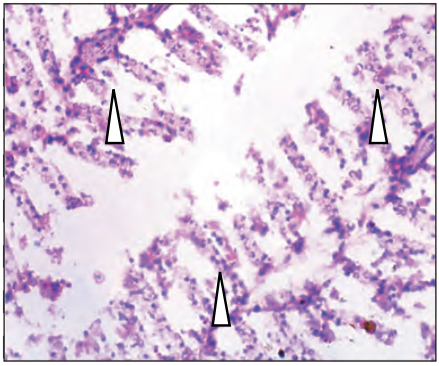

Fig.14. H & E stained photomicrograph of monocrotophos treated gill tissue of *L. rohita* showing epithelial cell erosion (arrows) in the Secondary Gill Lamellae. (x400)

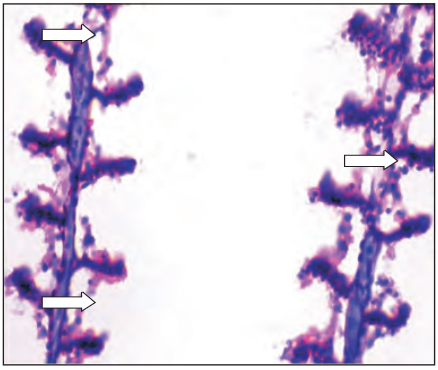

Fig.15. H & E stained photomicrograph of monocrotophos treated gill tissue of *L. rohita* showing epithelial cell necrosis and erosion in the Secondary Gill Lamellae (arrows) and dilation of Primary Gill Lamallae. (x400).

Table.2 Histomorphological changes in the fish gills during acute toxicity studies

Histopathological Changes	96 hrs						
	10	20	40	60	80	100	120
Hypertrophy of gill lamellae	0	0	1	2	2	2	3
Epithelial degeneration	0	0	1	2	2	3	3
Dilated capillaries	0	0	1	1	1	2	3
Epithelial necrosis	0	0	0	1	2	3	3
Clubbing and curling of lamellae	0	0	1	1	2	2	2

Gill Lesion Score: 0-Normal; 1-Mild; 2-Moderate; 3-Severe

Table.3 Histomorphological changes in the fish gills during chronic toxicity studies

Histopathological Changes	30 days					
	2	4	8	16	32	40
Hypertrophy of gill lamellae	1	2	2	2	3	3
Interlamellar Bridge Formation	1	2	2	2	3	3
Dilated capillaries	2	2	3	3	3	3
Epithelial necrosis	1	1	2	2	3	3
Epithelial erosion	1	2	2	2	3	3
Clubbing and curling of lamellae	1	1	1	2	3	3

Gill Lesion Score: 0-Normal; 1-Mild; 2-Moderate; 3-Severe

Effect on Liver

Histopathological changes observed in the liver histo-architecture included

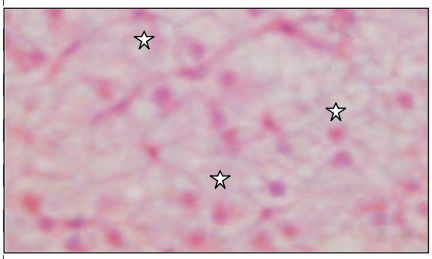

Fig.16. H & E stained photomicrograph of the liver of control fish *L.rohita* showing normal hepatocytes (asterisks) with little intercellular spaces.(x400).

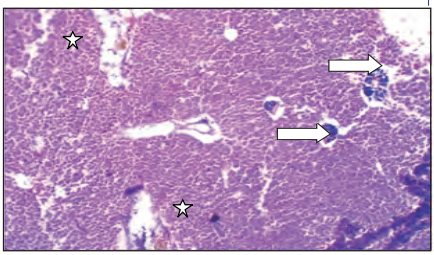

Fig.17. H & E stained photomicrograph of monocrotophos treated liver of *L. rohita* showing blood vessel with blood congestion / haemorrhages in blood vessels (asterisks) and distended sinusoids (arrows) between hepatocytes. (x200).

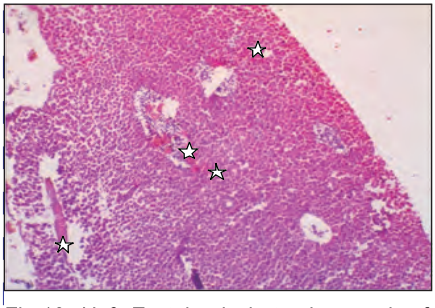

Fig.18. H & E stained photomicrograph of monocrotophos treated liver of *L. rohita* showing blood vessel with blood congestion(asterisks) . (x100).

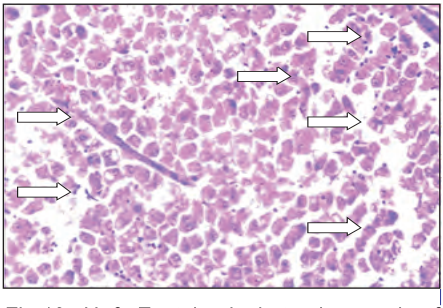

Fig.19. H & E stained photomicrograph of monocrotophos treated liver of *L. rohita* showing cytoplasmic vacuolization (arrows). (x400).

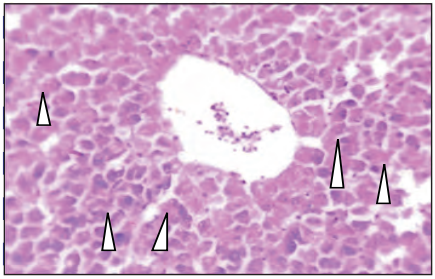

Fig.20. H & E stained photomicrograph of monocrotophos treated liver of *L. rohita* showing disintegration of hepatocytes with pyknosis (arrowheads). (x400).

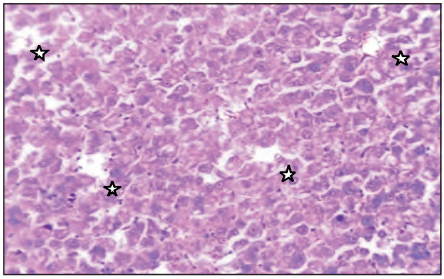

Fig.21. H & E stained photomicrograph of monocrotophos treated liver of *L. rohita* showing extensive cirrhosis (astrerisks) (x400).

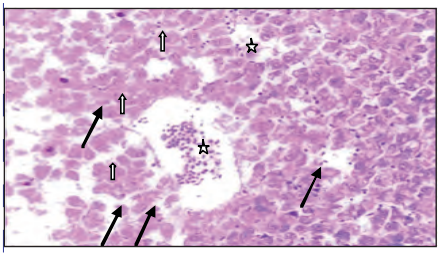

Fig.22. H & E stained photomicrograph of monocrotophos treated liver of *L. rohita* showing extensive cirrhosis(arrows) with release of pyknotic nuclei (asterisks) into the intercellular spaces. Hepatocytes are also showing the presence of pycnotic nucleus (arrows) (x400).

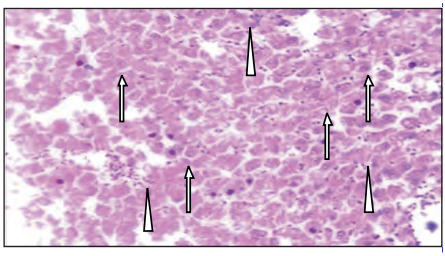

Fig.23. H & E stained photomicrograph of monocrotophos treated liver of *L. rohita* showing karyohexis (arrows) and karyopyknosis (Arrow head) (x400).

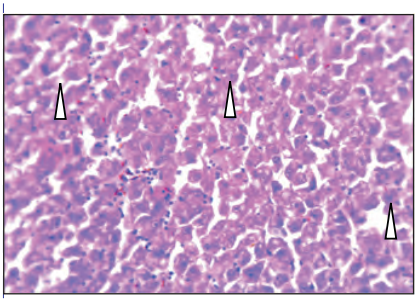

Fig.24. H & E stained photomicrograph of monocrotophos treated liver of *L.rohita* showing nuclear and cytoplasmic vacuolization(arrow heads) signifying hepatic degeneration (x400).

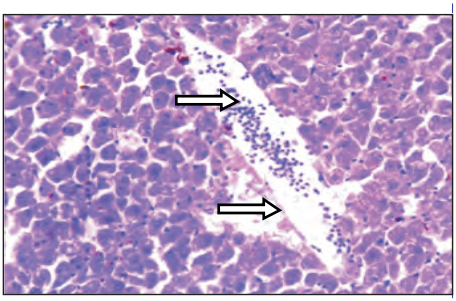

Fig.25. H & E stained photomicrograph of monocrotophos treated liver of *L.rohita* showing pyknotic nuclei in sinusoids (x400).

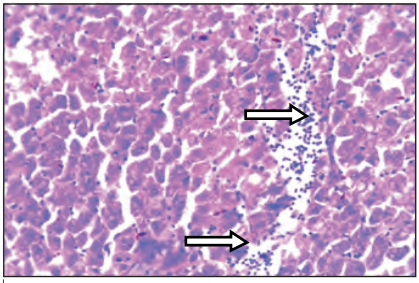

Fig.26. H & E stained photomicrograph of monocrotophos treated liver of L.rohita showing pyknotic nuclei released between sinusoids (arrows) (x400).

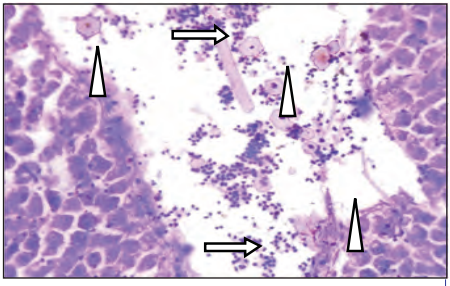

Fig.27. H & E stained photomicrograph of monocrotophos treated liver of *L. rohita* showing pyknotic nuclei (arrows) and disintegrated hepatocytes (arrow heads)from liver tissue (x400).

Effect on Intestine

Histopathological changes observed in the intestinal histo-architecture included

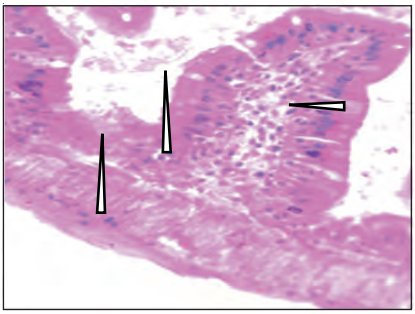

Fig.28. H & E stained photomicrograph of monocrotophos treated intestine of *L. rohita* showing cytoplasmic vacuolization in the intestinal epithelial cells (arrow heads) (x400).

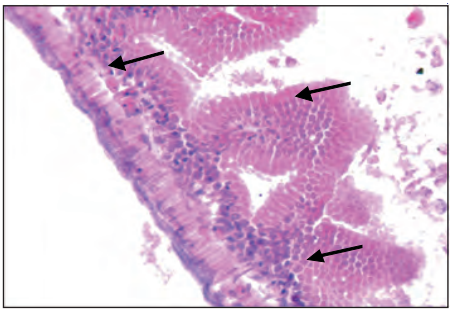

Fig.29. H & E stained photomicrograph of monocrotophos treated intestine of *L.rohita* showing cracked clay like appearance (arrows) (x400).

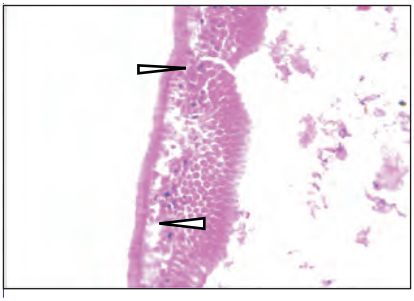

Fig.30. H & E stained photomicrograph of monocrotophos treatedintestine of *L.rohita* showing sloughing off sub mucosal layer, and circular and longitudinal muscle layer (arrows) (x200).

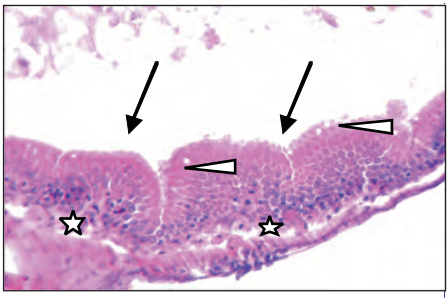

Fig.31. H & E stained photomicrograph of monocrotophos treated intestine of *L. rohita* showing cracked clay like appearance (arrows) and disintegrated submucosal and muscle layers (asterisks) and disintegration of lamina propria (arrow heads) (x400).

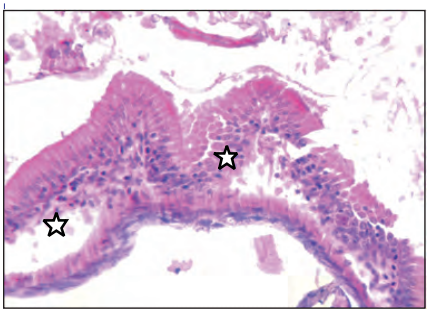

Fig.32. H & E stained photomicrograph of monocrotophos treated intesine of *L.rohita* showing sloughing of the epithelial layer and complete disintegration of intestinal of submucosa (asterisks) (x400).

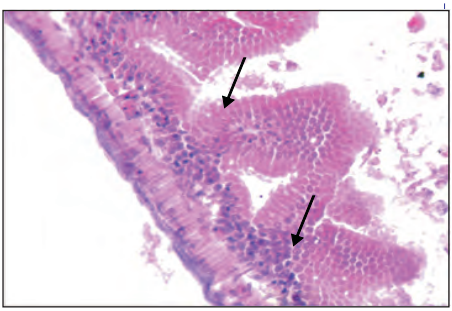

Fig.33. H & E stained photomicrograph of monocrotophos treated intestine of *L.rohita* showing cracked clay like appearance (arrows) with intact serosa (x400).

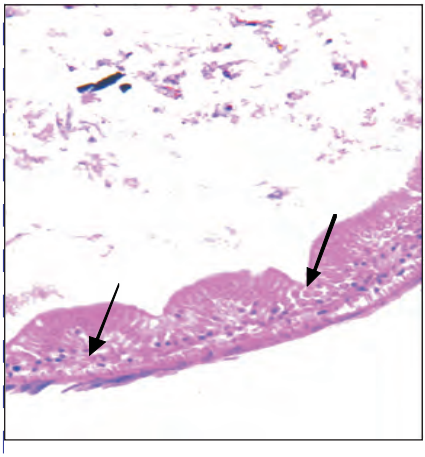

Fig.34. H & E stained photomicrograph of monocrotophos treated intestine of *L.rohita* showing naked nuclei and epithelial cells vacuolated (arrows) (x400).

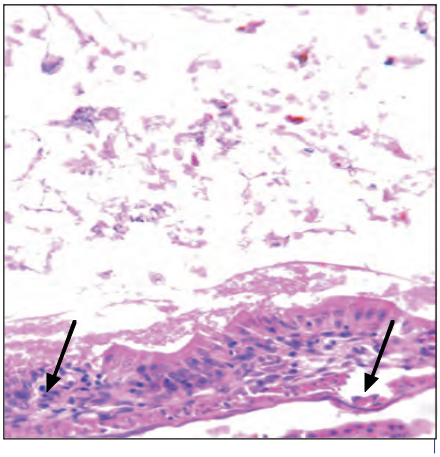

Fig.35. H & E stained photomicrograph of monocrotophos treated intestiner of *L. rohita* showing complete degeneration of the epithelium and the sloughing of the seroal layer from the intact epithelium (arrows) (x400).

DISCUSSION

Effect on behavioural changes

The abnormal behavioural responses observed in *Labeo rohita* when exposed to different concentrations of monocrotophos, is a mechanism in which fishes are trying to resist change in their normal aquatic environment. The nature and rapidity of onset of the behavioural response indicate that monocrotophos becomes active at neuromuscular system of *Labeo rohita.*

Animal behaviour is a neurotropically regulated phenomenon, which is mediated by neurotransmitters (Bullock *et al*., 1977).The stressful breathing behaviour exhibited by *Labeo rohita* may be the result of respiratory impairment due to the effect by monocrotophos on the gills (Shahi and Singh, 2010). The change in skin colour and scratching their nostril to bottom and frequently coming to the surface has been reported by Wade *et al*.,2002 and Oti, 2003 for *Oreochromis niloticus* exposed to Cassava effluent and Heteroclarias exposed to water extract of the bark of *Thevetia peruviana* respectively.

Effect on gill tissue

The gills being one of the most-vulnerable organs of the teleosts that come into a direct and immediate contact with the pollutant form an important organ for pathological studies. The gills are one of the most delicate structures of a teleost. As they have an external location, they are bound to come into contact with the medium (water).Thus, they are vulnerable and liable to be damaged by any irritant material, which may be dissolved or suspended in water (Sahoo *et al*., 2003). Severe changes in the gill architecture of fish have been observed in the past on exposure to mercury, zinc, pesticides, synthetic herbicide as well as effluents from tannery and textile mills (Das and Mukherjee, 2000; Regar and Bhatnagar, 2006; Bhatnagar *et al*., 2007; Jayachandran and Pugazhendy, 2009; Pathan *et al*., 2010).These studies indicated loss of microridges, fusion and thickening of gill lamellae along with increased production of mucous. Damage, fusion and clumping in the middle and distal parts of primary lamellae and swollen deterioration and modification of arborizing ridges into more expanded surface area in the secondary lamellae were also observed. Tilak *et al*., 2001 have reported progressive degeneration, bulging in tips of primary gill lamellae, club shaped secondary gill lamellae and severe necrotic changes in the epithelial cells of secondary gill lamellae of *Ctenopharyngodon idellus* (Valen.) caused

due to exposure to technical fenvalerate and EC 20%. They concluded that fenvalerate intoxication caused atrophy and complete fusion of secondary gill filaments, thereby, obliterating the interlamellar region. Similar clubbing of secondary gill lamellae and fusion of the lamellae has also been observed in the present study. This clubbing of lamella is due to the long-term response to lower levels of irritation called lamellar hyperplasia of the tissue. The cells are derived from the primary lamellae and they migrate distally, resulting in an accumulation of cells at the leading edge of secondary lamella. This is colloquially called 'clubbing' of lamella. The tip of the lamellae is clubbed because the pillar cells that join the dorsal surface of the lamella to the ventral surface are ruptured. This rupture causes dilation of the lamellar capillary and therefore the pooling of the blood (Roberts and Rodger, 2001). Massive lamellar hyperplasia may cause a solid fusion of many lamellar capillaries within a mass of hyperplastic epithelium leading to secondary lamellar fusion. Excessive secretion of mucus , lifting of the gill epithelium and the fusion of gill lamellae could be protective mechanism so as to reduce the vulnerability causedby the pesticide (Mallat, 1985).Riji John and Jayabalan (2007) have observed hyperplasia, lamellar fusion, curling and bulging of tips of primary gill lamellae, exudation of erythrocytes when fish Cyprinus carpio was exposed to sublethal concentration of endosulfan. Thus, to sum up, necrotic epithelial cells, lamellar hyperplasia, lamellar fusion, and clubbed tips of secondary lamellar have been observed in the present study. Hence, it can be correctly inferred that monocrotophos acts as a toxicant in a similar fashion as any other heavy metal, pesticides, effluent or a pollutant of chemical origin.

Effect on liver tissue

The liver is the primary organ for detoxification of xenobiotics (Metelev *et al*., 1971).Disturbed hepatocyte with loss of normal palisade arrangement was evident in the liver of *Labeo rohita* with increasing exposure to the monocrotophos. King (1962) found many small vacuoles in hepatic cells of brown trout fry and adult guppies exposed to monocrotophos. It appears to be a general feature of the liver of intoxicated fish that the degree of structural heterogeneity is enhanced with increasing concentration of toxicants (Hawkes, 1980 ; Paulose and Maheswari, 2006; Lognathan *et al*.,2006). Kabir and Begum (1978) and Narayan and Singh (1991) observed extensive degeneration of cytoplasm, with pyknosis in the liver tissue of *Heteropneustes fossilis* when subjected to acute thiodan toxicity. Appearance of many small vacuoles in the hepatic cells was reported in brown trout fry and adult guppies

when exposed to DDT and this they relate to resorption of fatty yolk (King,1962) and the degree of structural heterogeneity is enhanced with increasing concentration of toxicants (Hawkes,1980). Wide variety of insecticides and other toxic by-products tend to accumulate in high concentration within the liver (Hinsen *et al*., 1971; Metelev *et al* ., 1983) as liver is the major organ for detoxification (Dutta *et al*., 1993). Irregular nuclear profiles with scalloped edges, necrotic changes in nuclei, acute toxicity and cell death have been reported in fish when exposed to pesticides. Histological studies on the effect of endosulfan on liver tissue confirm similar toxicity to that of lindane in *Cyprinus carpio* (Mc Donald, 1983). Thus, the histoarcheitectural changes in the hapatocytes might be due to various protective mechanisms evoked by fish hepatocyte to combat with the sudden entry of monocrotophos for detoxification into liver.

Similar types of histological changes have been reported by Das and Mukherjee (2000) in various fresh water fish associated with zinc and copper toxicity. Our study revealed that copper sulphate and lead nitrate (Braunbeck et al., 1990) caused pathological changes such as karyopycknosis in hepatocytes, followed by karyorrhexis are the cytologic conditions, indicating that hepatocytes are undergoing necrosis.

These heavy metals can be taken up by the candidate fish through at least four routes; the food ingestion, simple diffusion via gills pore, through drinking process and by intestinal orskin absorption (Fanta et al.,2003). Similar findings were reported by Das and Mukherjee (2000) and Bhatkar (2011) in *L. rohita* upon exposure to sub-lethal doses of hexachloro-cyclohexane and heavy metals, respectively.

Effect on Intestinal tissue

The intestine showed disruption in the lining of the villi (De. Epi) and pyknosis (Py). Degeneration of tissue (DT) and of the epithelial lining was obvious. The structure of the cryptic cells was highly degenerated. After prolonged treatment extensive degeneration of intestinal villi, vocuolization and fibrosis occurred. Elongation of cryptic cells (ECC) and infiltration (I) was also seen. The changes were time and dose dependent. Similar damages were observed after exposing farmed fish *Ctenopharyngdon idella* (Grass carp) to sublethal contrations of potassium dichromate. Major histological changes were necrosis, pyknosis, degeneration of mucosal epithelium and extensive vacuolization. Our results were also comparable to that of who exposed *Channa punctatus* to 6.8mg/l of lead nitrate and observed in

intestine and pyloric caeca the flattening of villi, inflammation and necrosis. Tthe same results after exposing *Oreochromis niloticus* to cadmium. Major histological changes were degeneration of columnar epithelium, distortation of basement membrane of the villi, necrosed mucosa and submucosal hemorrhage. Cadmium treated rats showed shorter and thicker villi with a large number of vacuoles and infiltration of neutrophils in the lamina propria. *Cirrhinus mrigala* exposed to sub lethal concentrations (0.3ppb and 0.6ppb) of lambda cyhalothrin (a synthetic pyrethroid pesticide) observed intestinal lesions, infiltration of eosinophils into lamina porpia and atrophy of epithelial cells. Flattening and cracked clay appearance was observed by Bhatnagar and et al. (2007) after chronic exposure for 30, 60, 90 and 120 days of fingerlings of *Labeo rohita* to 15mg NaF/L.

CONCLUSIONS

It is evident from the present study that monocrotophos exposure at even lower concentrations causes severe pathological changes in the gill architecture and liver tissue of *Labeo rohita. Gill* is an important organ performing vital functions like respiration, osmoregulation, acid-base balance, excretion *etc.* An improper functioning of many organs/system will reflect detrimental changes in layer of epithelial cells covering blood passage of secondary lamellae. Necrotic epithelial cells, lamellar hyperplasia, lamellar fusion, and clubbed tips of secondary lamellar have been observed in the present study, which might be the reason for stressful behavior in *Labeo rohita* leading to respiratory impairments. Therefore, gill histology appears to be a sensitive monitoring tool to aquatic health. The histological alterations in the liver of *Labeo rohita* of experimental groups showed severe necrosis, and minor vacuolations, distended sinusoids and haemorrhages. The histoarcheitectural changes in the liver might be the protective mechanism evoked by *Labeo rohita* to combat with entry of monocrotophos for detoxification in liver. The study confirms monocrotophos to be a hepato as well a gill toxicant even at low concentration when exposed for long time.

Fish histopathology could therefore make valuable contribution in monitoring aquatic ecosystem and should form an important part of environmental impact assessment in the environmental management process.

REFERENCES

Agrahari S, Gopal K and Pandey KC (2006) Biomarkers of monocrotophos in a freshwater fish *Channa punctatus* (Bloch) *J Environ Biol* 27 453-457.

Ali D and Kumar S (2008) Long term genotoxic effect of monocrotophos in different tissues of freshwater fish *Channa punctatus* (Bloch) using alkaline single gel electrophoresis *Sci Total Environ* 405 345-350.

Aguiar LH. (2004) Metabolical effects of Folidol 600 on the neotropical freshwater fish matrinxã, *Brycon cephalus Environmental Research* 95 224-230.

Andre Luis da Cruz (2002) Sublethal concentrations of monocrotophos affect aggressive behaviour of fishes *Astyanax altiparanae* and Britski and *Oreochromis niloticus* (Linneaus) (teleostei, Cichlidae) *Rev Bras Zool* 19 268.

Anonymous (2003a) Pesticides in bottled water *The Times of India* NewDelhi 5 February.

Anonymous (2003b) Chew this: pesticides hit people, not pests *The Timesof India* New Delhi 16 April.

Anonymous (2003c) Colas fizz with pesticides. *The Times of India* NewDelhi 6 August

Banerjee SN (1979) Agricultural production through increased pesticides usages. *Pesticides*4 17-19.

Bhatia HL (1971) Toxicity of some insecticides to *Cirrhinus mrigala* and *Colisa faciata* J *Inland Fish Soc India* 2 114-116.

Bhatnagar VK (2001) Pesticide Pollution: Trends and Perspectives. ICMR Bulletin Division of Publication and Information, New Delhi 31 187-88.

Bhatnagar C, Bhatnagar M and Regar BC (2007) Fluoride induced histopathological changes in gill, kidney and intestine of freshwater teleost *Labeo rohita Res Rept* 40 55-61.

Bouregeois DP, Gaude P, Deveau P and Maller N (1993) Micro extraction of organophosphorus pesticides from environmental water analysis by gas chromatography *Bull Environ Contam and Toxicol* 50 433-440.

Bullock TH, Orkand R and Grinnella A (1977) *Introduction to Nervous system* WH Freeman and Company, Sanfrancisco.

Das BK and Mukherjee SC (2000) A histopathological study of carp (*Labeo rohita*) exposed to hexachlorocyclohexane *Veterinarski Arehiv* 70 169-180.

Dutta HM, Adhikari S, Singh NK, Roy PK and Munshi JS (1993) Histopathological changes induced by malathion in the liver of freshwater fish catfish, *Heteropneustes fossilis Bull Environ Contam Toxicol* 51 895-900.

Eichelberger JW and Lichtenberg JJ (1971) Persistence of pesticides in river water *Env Sci Tech* 5 541-544.

Gupta PC (1975) Neurotoxicity of chronic chlorinated hydrocarboninsecticide poisoning a clinical and electroencephalographic study in man. *Indian J. Med. Res* 63 601-606.

Gupta SK, Jain JP, Sayed HN and Kashyap SK (1984) Healthhazards in pesticide formulators exposed to a combination of pesticides. *Indian J. Med. Res* 79 666-672.

Gupta PK (1985**)** Pesticides. In: Gupta, P.K., Salunkhe, D.K. (Eds.),Modern Toxicology. Metropolitan Book Company, New Delhi, 1-60.

Gupta PK (1989) Pesticide production in India: an overview. In: Mishra,P.C. (Ed), Soil Pollution and Soil Organisms. Ashish Publishing House,New Delhi 1-16.

Gupta PK (2004) Pesticide exposure-Indian scene. *Toxicology* 198 8390.

Hawkes JW (1980) The effect of xenobiotic on fish tissues: Morphological studies *Fed Proc* 39 3230-3236.

Hinsen DJ, Parrish PR, Lower AJ, Wilson Jr and Wilson PD (1971) Chronic toxicity uptake and retension of Aroclor 1254 in two estuarine fishes *Bull Environ Contam Toxicol* 6 113-116.

Humason GL (1979) *Animal Tissue Techniques.* WH Freeman & Co., San Fansico.

Jayachandran K and Pugazhendy K (2009) Histopathological changes in the gill of *Labeo rohita* fingerlings exposed to Atrazine *Am Euras J Sci* Res 4 221-229.

Kabir SMH and Begum R (1978) Toxicity of three organophosphorus insecticides to singhi fish, *Heterpneustes fossilis Dhaka Univ Stud B* 26 115-122.

Kalavathy K Sivakumar AA and Chandran R (2001) Toxic effects of the pesticides Dimethoate on the fish *Sarotherodon mossambicus J Ecol Res Bioconserve* 21 27-32.

Karnik AB, Suthar AM, Patel MM, Sadhu HG, Venkaiah K and Nigam SK (1993) Immunological profile in workers exposed to pesticides *Indian J Ind Med.* 39 110-112

Karunakaran CO (1958) The Kerala food poisoning *J. Indian Med. Assoc* 31 204-205.

King SF (1962) Some effects of DDT on the guppy and brown trout *US Fish Wild life Servo Spec Sci Res Fis* 20 399.

Kumar S and Pant SC (1985) Renal pathology in fish (*Puntius conchonius*) following exposure to acutely lethal and sublethal concentrations of monocrotophos *Bull*

Environ Contam Toxicol 35 228-233.

Labeo rohita (TSN) 163681 Integrated Taxonomic Information System Retreived on 30 January 2006

Law JM (2003) Issues related to the use of fish models in toxicologic pathology: session introduction *Toxicol. Pathol.* 3149-52.

Lognathan K, Velmurugan B, Howrelia JH, Selvanayagam M and Patnail BB (2006) Zinc induced histological changes in brain and liver of *Labeo rohita* 27 107-110.

Malla FA , Sharma G and Singh S (2009) Chlorpyrifos pesticide toxicity on erythrocyte sedimentation rate in fish, *Channa punctatus Biol and Med* 2 54-55.

Mallat J (1985) Fish gill structural changes induced by toxicants and other irritants A Statistical Review *Can J Fish Aquat Sci* 42 630-648.

Mcdonald DG (1983) The effect of H-upon the gills of freshwater fish *Can J Zoo* 65 691-703.

Mercy TV, Madhusoodhanan AB and Nair JR (1996) Pesticide induced histological changes in juveniles of *Channa marulius Fourth Ind Fisheries Forum* Pp 81.

Metelev VV, Kanaev Al and Dzaskhava NG (1983) *Water Toxicology* Amerind Publishing Company Pvt Ltd New Delhi.

Metelev VV, Kanaev AL and Diasokhva (1971) *Water toxicity* American Publishing Co Pvt Ltd, New Delhi.

Narayan AS and Singh BB (1991) Histopathological lesions in *Heterpneustis fossilis* subject to acute thiodan toxicity *Acta Hydrochem Hydrobiol* 19 235-243.

Nayak AK, Raha R and Das AK (1995) Organochlorine pesticides in middle stream of Ganga river *Bull Environ Contam and Toxicol* 54 68-74.

Nigam SK, Karnik AB, Chattopadhyay P, Lakkad BC, Venkaiah K and Kashyap SK (1993) Clinical and biochemical investigations to evolve early diagnosis in workers involved in the manufacture of hexachlorocyclohexane. *Int Arch Occup Environ Health* 65 193.

Oloruntuyi OO, Mulero O and Odukale EB (2000) The effect of two pesticides on *Clarias gariepinus J Environ Biol* 173-177.

Oti EE (2003) Acute toxicity of water extracts of bark of *Thevetia Peruviana* to the African freshwater catfish *Heteroclarias* hybrid fingerling *J Fish Technol* 2 124-130.

Park D, Minor MD and Propper CR (2004) Toxic response of endosulfan to breeding and non-breeding female mosquito fish *J Environ Biol* 25 119-124.

Pathan TS, Thete PB Shinde SE, Sonawane DL and Khillare YK (2010) Histopathological changes in the gill of freshwater fish *Rasbora daniconius* exposed to

paper mill effluent Iranica J Energy Envn 1 170-175.

Paulose PV and Maheshwari K (2006) Hepatocyte damage in Indian Major carp *Labeo rohita* with respect to accumulation and elimination of mercury *Asian J Exp Sci* 2 369-374.

Rao VJ, Begum G, Sridhar V and Chakrareddy N (2005) Sublethal effects of monocrotophos on locomotor behavior and gill architecture of the mosquito fish, *Gambusia affinis J Environ Sci Health* 40 813-825.

Rathod ND and Kshirsagar BV (2010) Quantification of nucleic acid from freshwater fish *Punctius arenatus* exposed to pesticides *Int J Adv Biotech Res* 1 43-51.

Regar BC and Bhatnagar C (2006) Histopathological changes in the gill archeitecture of freshwater teleosts *Labeo rohita* exposed to sodium fluoride *J Her Med and Toxicol* 1 35-41.

Riji John and Jayabalan N (2007) Sublethal effects of endosulfan on the histology and protein pattern of *Cyrinus carpio* gill *J Appl Ichthyology* 9 49-56.

Rita P, Reddy PP and Reddy SV (1987) Monitoring of workers occupationally exposed to pesticides in grape gardens of Andhra Pradesh *Environ. Res* 44 1-7.

Roberts RJ and Rodger HD (2001) *The Pathophysiology and Systematic pathology of teleosts In fish pathology* Roberts Harcourt Publishers Ltd, London .

Sahoo PK, Mukherjee AK, Jain AK and Mukherjee A (2003) Histopathological and Electron microscopic studies of gills and ophisthonephros of Rohu, *Labeo rohita* to acute and subchronic aflatoxin B1 toxicity *Asian Fish Sci* 16 257-268.

Selvarani D and Rajamanickam C (2003) Toxicity of PCB 1232 on mitochondria of fish *Arius caelatus Ind J Exp Biol* 41 336-340.

Shahi J and Singh A (2010) A comparative study on the piscicidal activity of synthetic and plant origin pesticides, to fish Channa Punctatus *World J Zool* 5 20-24.

Simon LM et al. (1983) *Comp Biochem Physiol* 75 1 67-169 .

Stegman JJ et al. (1992) Lewis Publishers Boca Raton, Florida.

Thomas PC and Murthy TL (1976) Studies on the impact of a few organic pesticides on certain fish enzymes *Ind J Anim Sci* 46 619-624.

Tilak KS, Veeriah K and Yacobu K (2001) Studies of histopathological changes in the gill, liver and kidney of *Ctenopharyngodon idellus* exposed to technical fenveralate and EC20% *Poll Res* 20 387-393.

Wade JW, Omregie E and Ezenwaka I (2002) Toxicity of cassava effluent on the Nile Tilapia *Oreochromis niloticus* under laboratory conditions J Aqua Sci 17 89-94.

WHO (1989) *Environ Hlth Crit 82 Geneva Switzerland: United Nations Environment Programme*, International Labor Organization and WHO.

Yaji AJ and Auta J (2007) Sublethal effects of monocrotophos on some haematological indices of African catfish *Clarias gariepinus J Fisheries*

But man is a part of nature, and his war against nature is inevitably a war against himself."

Rachel Carson

Department of Zoology, Mercy College, Palakkad, Kerala
(Re-accredited with A grade by NAAC)

www.mercycollegepalakkad.com, email: zoology@mercycollegepalakkad.com